



GLUBRAN<sup>®</sup>2

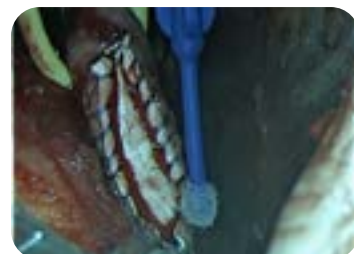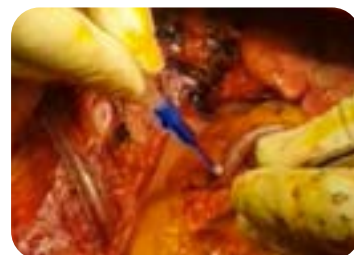# Cardiac & Vascular Surgery

## Sealant, adhesive, haemostatic, bacteriostatic



### Indicated use <sup>1-8</sup>

- Repair of epicardial lacerations without the use of sutures.
- Haemostasis and reinforcement of aortic, coronary and vascular sutures, both vessel-vascular and prosthetic-vascular, in particular in the presence of calcific or atheromatous vessels.
- Consolidation of coronary artery bypass anastomoses.
- Patch fixation on cardiac tissue.
- Bonding of the dissection plane in acute aortic dissections.



Authorised for use in adult and paediatric patients

In type A aortic dissection the polymerization speed, adhesiveness and elasticity of Glubran<sup>2</sup> allow aortic stump reconstruction in a shorter time than with GRF glue... the simple and fast procedure allows for a larger bonding area of the dissected layers...<sup>8</sup>

Effective suture reinforcement in left ventricular reduction in 14 patients:  
...the free wall of the ventricle is closed in a linear way using a full-thickness suture with Teflon strips and Glubran<sup>2</sup> ...<sup>6</sup>

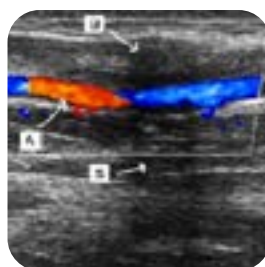
In patch repair of small post-infarct ruptures of the left ventricle, Glubran<sup>2</sup> ensures patch adhesion and reduces:

- myocardial trauma
- the additional ischemia
- aortic clamping times...<sup>5</sup>

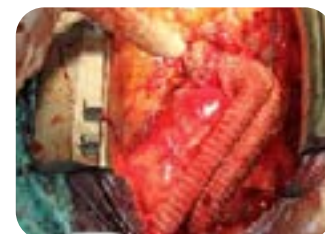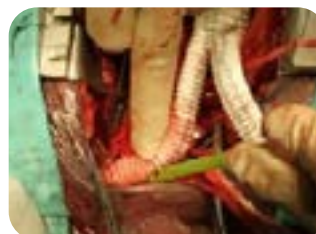In the Transealing technique, Glubran<sup>2</sup> can be successfully used, as a liquid embolic agent, to block the blood loss supplying the aneurysmal sac of Type II Endoleaks...<sup>11</sup>




Effectively applied in the fixation of omentum on an area of ischemic myocardium for an alternative therapeutic approach in rescuing infarcted myocardium ...<sup>3</sup>

... 0.1.0.2 ml of Glubran<sup>2</sup> is applied to the healthy areas of the myocardium to fix the pericardial fat flap over the ischemic area...  
Less oedema and more recovered cardiac tissue with reduction in the infarcted area were observed in treated animals ...<sup>3</sup>



**Effective and safe in the resolution of iatrogenic pseudoaneurysms with percutaneous ultrasound-guided technique.** The injection of Glubran<sup>2</sup> induces the successful disappearance of the pseudoaneurysmatic chamber even in PSA complicated by nerve/venous compression and/or tissue necrosis...<sup>10</sup>



	DISTANCE FROM THE TISSUE	SPRAY DIAMETER	INTENDED USE	VASCULAR AND CARDIAC
<b>THIN FILM APPLICATION DEVICE</b> G-DT 	In contact	-	For linear, point-like or very small surfaces applications	Sealing and reinforcement of suture lines
<b>SHORT SPRAY DEVICE</b> G2-NBT SHORT 	5-7 cm	4 cm	On large surfaces	Sealing, haemostasis, reinforcement of manual or mechanical sutures and bonding of the dissection plane
<b>SHORT MINI SPRAY DEVICE</b> G2-NBT SM SHORT 	2-3 cm	1 cm	On small surfaces	

## Bibliography

- Gargiulo G, Pace Napoleone C, Solinas M, Frascaroli G, Pierangeli A. A new patch for the Norwood procedure. *Ann Thorac Surg.* 1999 Nov;68(5):1873-4.
- Paéz JM, San martin AC, Herrero EJ, Millan I, Cordon A, Rocha A, Maestro MA, Tellez G, Castillo-Olivares JL. Resistance and stability of a new method for bonding biological I materials using sutures and biological adhesives. *J Biomater Appl.* 2005 Jan;19(3):215-36.
- Gcllvez-Montén C, Prat-Vidal C, Roura S, Farré J, Soler-Botija C, Llucià-Valldeperas A, Dfaz-GUemes I, sanchez-Margallo FM, Arfs A, Bayes-Genis A. Transposition of a pericardial-derived vascular adipose flap for myocardial salvage after infarct. *Cardiovasc Res.* 2011 Sep 1;91(4):65.
- Gomes WJ, Underwood M, Asciane R, Lloyd CT, Angelini GD. Treatment of delayed rupture of the left ventricle after mitra I valve replacement. *Arq Bras Cardiol.* 2002 Nov;79(5):544-9.
- Alamanni F, Fu mero A, Parolari A, Trabatttoni P, Cannata A, Berti G, Biglieli P. Sutureless double-patch-and-glue technique for repair of subacute left ventricular wall rupture after myocardial infarction. *J Thorac Cardiovasc Surg* 2001 Oct;122(4):836-7.
- Birdi I, Bryan AJ, Mehta D, Pryn S, Walsh C, Wilde P, Angelini GD. Left ventricular volume reduction surgery. *Int J Cardiol.* 1997 Dec 1;62 Suppl 1:S29-35.
- Urbanski PP. When is tota I aortic arch replacement indicated in patients with acute aortic dissection. *Med Sci Monit.* 2002 Mar;8(3):CR165-8.
- De Paulis R, Matteucci SL, Penta de Peppo A, Chiariello L. Cyanoacrylate glue as an alternative to an additional suture line in the repair of type A aortic dissection. *Tex Heart Inst J.* 1999;26(4):275-7.
- Coppi G, Saitta G, Coppi G, Gennai S, Lauricella A, Silingardi R. Transealing: a novel and simple technique for embolization of type 2 endoleaks through direct sac access from the distal stent-graft landing zone. *Eur J Vasc Endovasc Surg.* 2014 Apr;47(4):394-401. doi: 10.1016/j.ejvs.2014.01.013. E pub.
- Del Corso A, Vergaro G. Percutaneous Treatment of Iatrogenic Pseudoaneurysms by Cyanoacrylate-Based Wall-Gluing. *Cardiovasc Intervent Radiol.* 2013 Jun;36(3):669-75.
- Ameli-Renani, S., Pavlidis, V. & Morgan, R.A. Secondary Endoleak Management Following TEVAR and EVAR. *Cardiovasc Intervent Radiol* 43, 1839–1854 (2020).

